



Research Article

NON-FUNCTIONING ADRENAL CARCINOMA IN PEDIATRICS: CASE REPORT

Yadira Melchor Vidal¹, Rocío Cárdenas Cardós², Jaime Shalkow Klincovstein³, Mario García⁴, César Cárdenas Pérez Gallardo⁵ and Alejandro Osvaldo Amador Pérez⁶

¹Pediatric Oncologist. Hematopoietic Progenitor Cell Transplantation

²Pediatric Oncologist. ABC Medical Center Observatory Campus. CDMX

³Surgeon Oncologist Pediatrician. ABC Medical Center Observatory Campus. CDMX

⁴Surgery. ABC Medical Center Observatory Campus. CDMX

⁵Radiology Oncologist. INCAN. CDMX

⁶Pediatric Hematologist. Hematopoietic Progenitor Cell Transplantation. ABC Medical Center Observatory Campus. CDMX

ARTICLE INFO

Article History:

Received 11th September, 2024

Received in revised form 24th September, 2024

Accepted 21st October, 2024

Published online 28th October, 2024

Key words:

Adrenal carcinoma, pediatrics, non-functioning adrenal carcinoma.

Introduction

ABSTRACT

Adrenal carcinoma is a rare disease with an annual worldwide incidence of 20,000 to 30,000 cases/million children under 15 years of age. This disease in the pediatric population is associated with virilizing features and hypercortisolism in most cases. Malignancy is defined when local invasion or metastasis is found, and is associated with a poor prognosis.

The rarity of this disease makes it a real challenge. This case is a male patient, 6 years 10 months old, who had no significant past history.

He had been suffering for 5 months of evolution, had incidental fever, multiple antibiotic and antipyretic treatments, without improvement. Physical examination revealed pale skin, malnutrition, mobile adenomegaly at submandibular level, hepatomegaly of 4 cm, non-painful abdomen. No clinical data of virilization. Rest of exploration without pathological data.

Image studies were performed as abdominal ultrasound, which reported a tumor dependent on the right adrenal gland, in addition to liver parenchyma with multiple calcifications. Confirming the diagnosis with abdominal tomography in which heterogeneous hepatic lesion with lobulated edges is reported, which displaces intra-abdominal structures, not being able to distinguish structures such as kidney or adrenal gland. As well as a PET CT with hyperfunctioning lesions in liver, lung and kidney.

The rarity of this disease, the differential diagnosis with other oncologic pathologies corresponding to the age group, and the frequent delay in diagnosis, contribute to the lack of understanding of this neoplasm and advanced stages at diagnosis. The prognosis of pediatric adrenal carcinoma is poor, with a 5-year event-free survival of 37%, associated with the lack of response to the few existing treatments, especially in non-functional carcinomas.

Copyright© The author(s) 2024, This is an open-access article distributed under the terms of the Creative Commons Attribution License, which permits unrestricted use, distribution and reproduction in any medium, provided the original work is properly cited.

INTRODUCTION

Adrenal carcinoma represents 0.2% of malignant neoplasms in childhood and adolescence, with a worldwide annual incidence of 20,000 to 30,000 cases per million. ⁽¹⁾ It is more common in female patients with a 2:1 ratio.

Despite the lack of consensus on the efficacy of mitotane adrenolytic agent and cytotoxic chemotherapy in pediatric

*Corresponding author: Yadira Melchor Vidal

Pediatric Oncologist. Hematopoietic Progenitor Cell Transplantation

patients, these therapeutic modalities have been indicated in unresectable cases or metastatic disease. ⁽²⁾

It has a bimodal distribution, with a first peak in children under 5 years of age and a second peak in adults in their fourth to fifth decades of life. It remains a difficult disease to treat, with a 5-year survival of 10% to 25% and a median survival from diagnosis of approximately 14.5 months. Most cases are sporadic, but may be a component of a hereditary syndrome (Li-Fraumeni syndrome, Beckwith-Wiedemann syndrome, and multiple endocrine neoplasia type 1 [MEN-1]). ⁽³⁾

It can be functioning when it produces more hormone than normal or non-functioning, when it does not produce more hormone than normal. Most tumors of the adrenal cortex are

functioning; non-functioning tumors predominate in the fourth and seventh decades of life, with male predominance (4).

Treatment includes complete surgical resection, which is the treatment of choice, as long as the tumor is resectable. Surgery is also indicated in stage IV, when it is considered that the primary tumor and metastases can be removed, with removal of more than 90% of the tumor mass.

Adjuvant medical treatment is aimed at controlling tumor growth and any hormonal hypersecretion. Control of hormonal secretion can be achieved with drugs that block steroidogenic enzymes. For this reason, in patients with hypersecretory carcinoma, the use of mitotane is the best option (5).

The stage of the disease is graded from I to IV, according to the TNM classification proposed by ENSAT (European Network for the Study of Adrenal Tumors).

This staging system defines stages I and II as strictly localized tumors, with a size less than or equal to 5 cm or greater than 5 cm respectively. Stage III tumors are characterized by infiltration of surrounding tissues, positive regional lymph nodes or a tumor thrombus in the vena cava and/or renal vein (6).

Stage IV is defined by the presence of distant metastases. To detect early metastatic disease.

ENSAT staging of adrenocortical carcinoma

system and the 2008 ENSAT-staging system for adrenocortical carcinoma.		
Stage	2004 UICC-staging system	2008 ENSAT-staging system
I	T ₁ N ₀ M ₀	T ₁ N ₀ M ₀
II	T ₂ N ₀ M ₀	T ₂ N ₀ M ₀
III	T ₁₋₂ N ₁ M ₀	T ₁₋₂ N ₁ M ₀
IV	T ₃ N ₀ M ₀	T ₃₋₄ N ₀₋₁ M ₀
	T ₁₋₄ N ₀₋₁ M ₁	T ₁₋₄ N ₀₋₁ M ₁
	T ₃ N ₁ M ₀	
	T ₄ N ₀₋₁ M ₀	

T1, tumor size ≤5 cm; T2, tumor size >5 cm; T3, tumor infiltration to neighboring tissues; T4, tumor invasion to adjacent organs or venous tumor thrombus in vena cava or renal vein. N0, negative lymph nodes. N1, lymph node(s) positive; M0, no distant metastases; M1, presence of distant metastases. Abbreviations: ENSAT, European Network for the Study of Adrenal Tumors; M, metastasis; N, lymph node; T, tumor.

Had been suffering from a 5-month history of illness, presenting an incidental fever of up to 39 degrees Celsius, predominantly at night, having visited multiple pediatricians and receiving different antibiotic and antipyretic treatments, with no improvement of the symptoms.

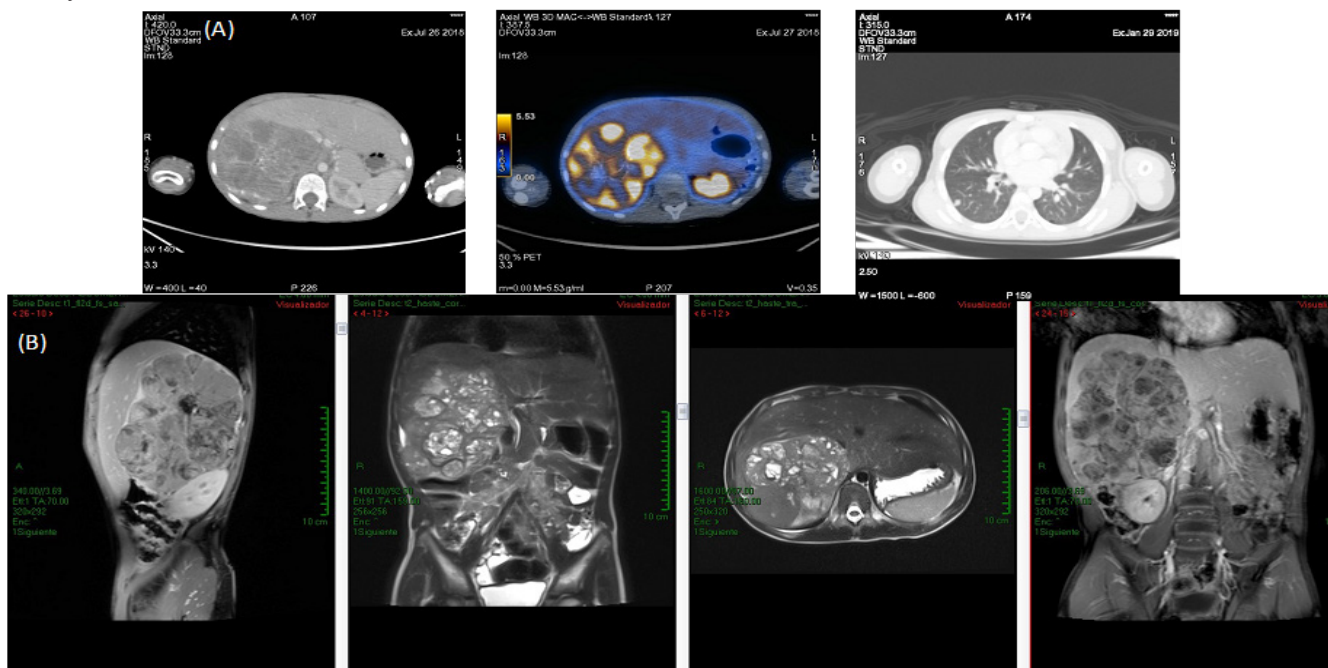


Image 1. (A) Diagnostic CT scan (2018): heterogeneous liver lesion with lobulated edges, which displaces intra-abdominal structures, not being able to distinguish structures such as kidney or adrenal gland. (B) MRI: hyperintense lesion at the liver level, which is observed displaced (12.5 x 9.2 x 8.5).

Clinical Case

Male patient, 6 years 10 months old, in the first year of elementary school, with the following history:

Family history: maternal grandmother with breast cancer. Maternal aunt: Immunological disease, does not remember variety.

Non-pathological history: questioned and denied.

Pathological history: allergies to shellfish and nuts

Physical examination revealed pallor of the teguments, moderate malnutrition, movable adenomegaly at submandibular level, hepatomegaly of 4 cm, non-painful abdomen, palpable liver of hard consistency. No clinical data of virilization. Rest of examination without pathological data.

Laboratory thrombocytosis of 671,000/mm³, ferritin 880.9 ng/ml, erythrocyte sedimentation rate 100 sec and c-reactive protein 7.3 mg/dl, as well as elevation of alkaline phosphatase 115 U/L. No elevation of ACTH, cortisol, or altered hormonal profile.

Study	11 May 2018	11 July 2018	24 July 2018
TGO	100	48	46
TGP	16	8	9
FA	1088	838	1115
GGT	14	14	18
HE	17	24	27
leukocytes	14,700	9900	11,100
neutrophils	46		
lymphocytes	34		
Hb	13.8	13	11.6
platelets	421 mil	595 mil	671 mil
reticulocytes			2.3
VSG			100
PCR			7.32
ferritin	468		880.97
procalcitonin			0.25

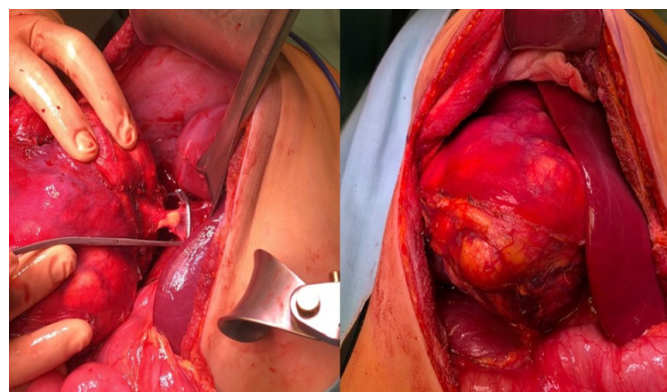


Image 2. Photographs provided by Dr. Jaime Shalkow

Pathology report: Low grade adrenal cortical carcinoma with extracapsular extension (Image 3).

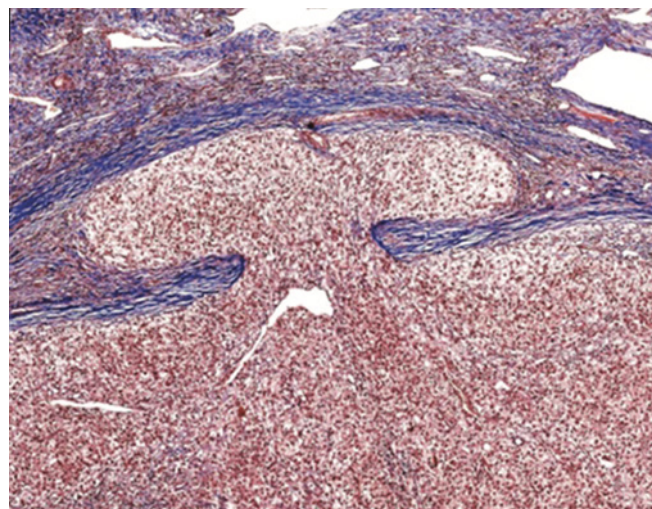


Image 3 Pathology slice, showing monotonous population, with abundant mitotic figures.

Image studies confirmed the diagnosis of a right adrenal tumor.

The differential diagnosis with a non-androgen-producing adrenal adenoma is histopathologic, excluding invasion of the adrenal capsule or permeation of the blood vessels.

With clinical suspicion of liver tumor, an abdominal ultrasound was performed, in which hepatomegaly was reported, with multiple calcifications. Right kidney lobulated, with multiple calcifications. Therefore it was decided to perform an abdominal tomography. Described in image 1.

As a first therapeutic approach, complete resection of retroperitoneal tumor dependent on the right adrenal, removal of thrombus from the inferior vena cava adjacent to the tumor with evaluation of lymph nodes was performed (Image 2).

With the diagnostic approach performed and following the ENSAT criteria, it is staged as stage IV.

The adrenal tumor must be surgically removed for definitive diagnosis. The immediate course of action is total tumor resection as this is the only potentially curative treatment, since adrenal carcinoma is not sensitive to chemotherapy or

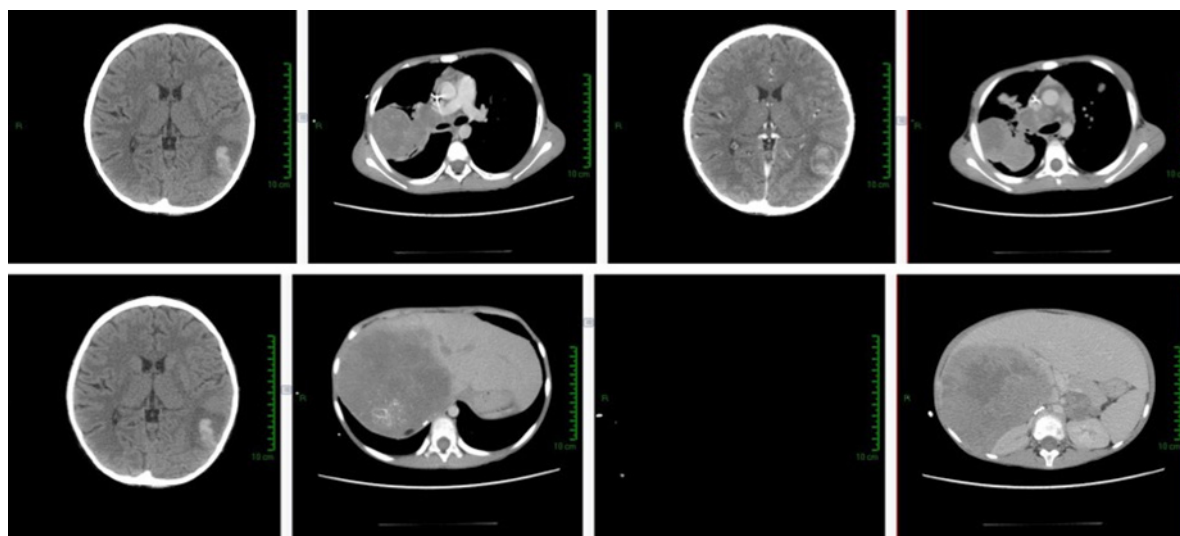


Figure 4. Hyperdense lesion associated with perilesional edema in the right frontal lobe measuring 2.3 x 2.5 cm. Multiple pulmonary nodules. Lesion in right paratracheal mediastinum of 4 x 3 cm. Hepatic parenchymal lesions of 12.3x 13 cm in segment 7 and 8. Hypodense pancreatic lesion of 3 x 2 cm.

radiotherapy. At the time of diagnosis 60% of patients have limited disease and the tumor can be completely resected.

He received 3 cycles with FIRM-ACT protocol: Doxorubicin 40 mgm² D1, etoposide 100mgm² D2-D4, CDDP 40mgm² D3-4 and mitotane 1.5g daily (unsuspended) every 28 days.

At the end of 3 cycles, the patient was evaluated and found progression of the disease at hepatic level and new pulmonary nodules.

Due to the progression, chemotherapy treatment was suspended and it was decided to use second line resources.

Due to the difficulty of the case and not having more chemotherapy resources, microwave ablation of hepatic lesions was performed, managing to maintain stable disease.

The patient underwent surveillance with monthly tomographic follow-up, presenting progression of the disease 1 year later. During the surveillance period he maintained an adequate quality of life, he was maintained with Lansky 100.

The patient died in May 2020, in this year he was already under palliative follow-up.

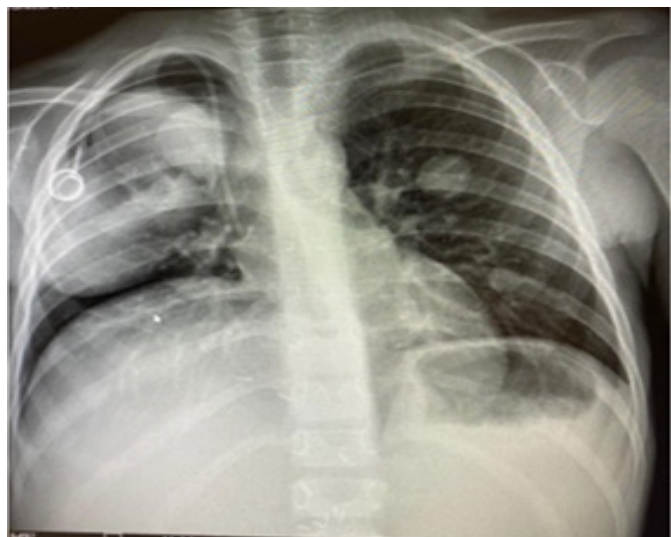

Figure 5. Radiopaque lesion encompassing the right hemithorax, in addition to multiple well-defined lesions, characteristic of pulmonary metastasis.

DISCUSSION

The rarity of this disease, the differential diagnosis with other oncologic pathologies corresponding to the age group, and the frequent delay in diagnosis, contribute to the lack of understanding of this neoplasm and advanced stages at diagnosis. The prognosis of pediatric adrenal carcinoma is poor, with a 5-year event-free survival of 37%, associated to the lack of response to the scarce existing treatments, especially in non-functional carcinomas (6).

In children with advanced disease as in the case of our patient, medical therapy should be instituted as soon as the diagnosis is made. So far, the first-line regimens are mitotane monotherapy; etoposide, doxorubicin, cisplatin plus mitotane; or streptozotocin plus mitotane. Since it was a non-functioning carcinoma, the use of mitotane was not indicated (7).

In patients with tumor progression in spite of first line medical

therapy, they are considered candidates for alternative regimens as occurred in this patient, but even with the use of different resources the prognosis does not change (8).

Our patient had all the unfavorable criteria (Weiss criteria), which further darkened his prognosis. However, he still achieved quality of life 2 years after diagnosis, exceeding the survival expectancy according to what is reported in the international literature.

Unfavorable Patient Factors		
tumor weight 756.3 gr	tumor size 13 x 10 x 9.5 cm	p53 presence
capsule invasion	Necrosis 40%	
Age (6 years)	Mitotics Figures	
		FAVORABLE FACTOR Complete Resec- tion

In recent years great advances have been made to try to improve the prognosis of patients, making way for new therapies, as in this case microwave ablation. The treatment of patients with non-functioning adrenal carcinoma requires the collaboration of a multidisciplinary team, including surgeon, Oncologist and endocrinologist.

Preoperatively, a complete study of adrenal production hormones and precursors should be performed in order to identify potential tumor markers and provide the patient with a stress dose of glucocorticoids prior to tumor resection. Glucocorticoid therapy in stress situations should be maintained during treatment until normal function of the adrenal cortex is confirmed.

In view of the difficulty of diagnosis, image techniques have improved greatly, including, in addition to CT and MRI. PET generates less radiation exposure and faster imaging, and can be used with FDG.

The treatment of all these tumors is fundamentally surgical, with chemotherapy playing a relevant role, especially in stage III.

Bioethical Aspects

The present study was performed under the informed consent of the patient's parents, with total confidentiality of personal data.

Conflict of Interest

The authors report no conflicts of interest.

References

1. Sandru F, Petca RC, Carsote M, Petca A, Dumitrascu MC, Ghemigian A. Adrenocortical carcinoma: Pediatric aspects (Review). *Exp Ther Med.* 2022 Apr;23(4):287.
2. Longui CA. ADRENAL CORTICAL CARCINOMA IN INFANCY. *Rev Paul Pediatr.* 2019 Jan-Mar;37(1):2-3.
3. Brondani VB, Fragoso MCBV. Pediatric adrenocortical tumor - review and management update. *Curr Opin Endocrinol Diabetes Obes.* 2020

- Jun;27(3):177-186.
4. Rodriguez-Galindo C, Krailo MD, Pinto EM, Pashankar F, Weldon CB, Huang L, Caran EM, Hicks J, McCarville MB, Malkin D, Wasserman JD, de Oliveira Filho AG, LaQuaglia MP, Ward DA, Zambetti G, Mastellaro MJ, Pappo AS, Ribeiro RC. Treatment of Pediatric Adrenocortical Carcinoma with Surgery, Retroperitoneal Lymph Node Dissection, and Chemotherapy: The Children's Oncology Group ARAR0332 Protocol. *J Clin Oncol*. 2021 Aug 1;39(22):2463-2473.
 5. Li J, Zhang W, Hu H, Zhang Y, Wen Y, Huang D. Adrenocortical Carcinoma in Eight Children: A Report and Literature Review. *Cancer Manag Res*. 2021 Feb 11; 13:1307-1314.
 6. Kostiainen I, Hakaste L, Kejo P, Parviainen H, Laine T, Löyttyniemi E, Pennanen M, Arola J, Haglund C, Heiskanen I, Schalin-Jääntti C. Adrenocortical carcinoma: presentation and outcome of a contemporary patient series. *Endocrine*. 2019 Jul;65(1):166-174.
 7. Varghese J, Habra MA. Update on adrenocortical carcinoma management and future directions. *Curr Opin Endocrinol Diabetes Obes*. 2017 Jun;24(3):208-214.
 8. Monteiro NM, Rodrigues KE, Vidigal PV. Adrenal carcinoma in children: longitudinal study in minas gerais, Brazil. *Rev Paul Pediatr*. 2018; 37(1):20-26
 9. Ribeiro RC, Pinto EM, Zambetti GP, Rodriguez-Galindo C. The international pediatric adrenocortical tumor registry initiative: contributions to clinical, biological, and treatment advances in pediatric adrenocortical tumors. *Mol Cell Endocrinol*. 2012; 351:37-43.
 10. Kerkhofs TM, Ettaieb MH, Verhoeven RH, Kaspers GJ, Tissing WJ, Loeffen J. Adrenocortical carcinoma in children: First population-based clinicopathological study with long-term follow-up. *Oncol Rep*. 2014; 32:2836-2844.

How to cite this article:

Yadira Melchor Vidal *et al.* (2024) Non-functioning adrenal carcinoma in pediatrics: case report, *International Journal of Current Advanced Research*, 13(10), pp.3316-3320
