

Research Article**AMYAND'S HERNIA: A CASE REPORT AND REVIEW OF LITERATURE****Dr. Ravinder Kumar, Dr. Junaid Nabi Wani, Dr. Deepti Chanjotra, Dr. Syed Ajaz**

Government Medical College, Kathua , Jammu & Kashmir

ARTICLE INFO**Article History:**Received 6th May, 2024Received in revised form 22nd May, 2024Accepted 16th June, 2024Published online 28th June, 2024**Key words:**

Amyand's hernia, Herniotomy, Hernioplasty, Appendix, Polypropylene

ABSTRACT

An amyand's hernia is an inguinal hernia containing the vermiform appendix with an incidence between 0.4% and 1% of all inguinal hernias. Acute or perforated appendicitis can complicate amyand's hernia. Its pre-operative diagnosis is rare and it is commonly diagnosed intra-operatively. Treatment of amyand's hernia depends on the status of the appendix and is guided by the Losanoff and Basson classification system. We report the case of a 55 years old male who presented to surgery OPD with complaints of swelling in the right groin since last 5 years. There was no history of pain in the groin or pain abdomen or vomiting. Examination of the patient revealed an indirect, incomplete, reducible inguinal hernia on right side with a positive cough impulse. After all baseline investigations, the patient was planned for elective mesh repair of the hernia. Intra-operative findings included a large indirect inguinal hernia sac containing a normal appearing appendix as its content. Herniated contents were reduced into the abdominal cavity, herniotomy was done and a polypropylene mesh was used for hernioplasty. The postoperative outcome was favorable.

Copyright© The author(s) 2024. This is an open access article distributed under the Creative Commons Attribution License, which permits unrestricted use, distribution, and reproduction in any medium, provided the original work is properly cited.

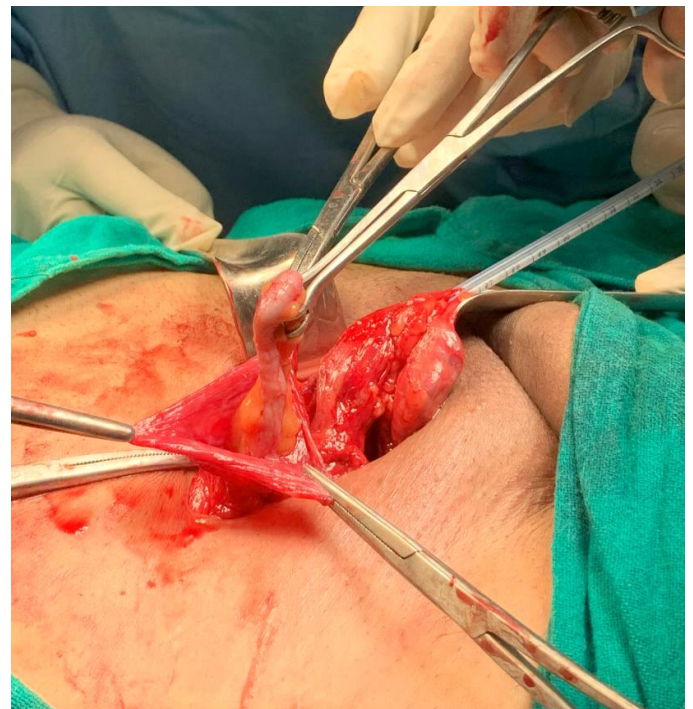
INTRODUCTION

An Amyand's hernia is a rare disease where the appendix is found within an inguinal hernia sac. In 1735, Dr. Claudius Amyand (the French born English Surgeon) first described an 11-year-old boy with an incarcerated inguinal hernia containing a perforated appendix¹. Subsequently, this type of hernia was named Amyand's hernia, which is rarely encountered in clinical practice. The incidence of finding an appendix within the hernia sac is rare, occurring in less than 1% of inguinal hernia patients and when complications arise such as inflammation, perforation or abscess formation, it becomes exceptionally rare with an incidence of about 0.1%².

CLINICAL CASE

A 55 years old male presented to Surgery OPD with complaints of swelling in the right groin since last 5 years. The swelling appeared on straining and while doing heavy work and disappeared on lying down. There was no history of pain in the groin or pain abdomen or vomiting. On examination, the swelling was an indirect, incomplete, reducible inguinal hernia on the right side which was confined to the inguinal canal and cough impulse was positive. All baseline investigations were done and the patient was planned for elective mesh repair of the hernia. On exploration of the inguinal canal, the sac of indirect inguinal hernia was identified and dissected off from the cord contents. On inspection of the sac, appendix was found to be the content of the sac. Appendix was normal in appearance with no signs of inflammation. Contents were reduced into the abdominal

cavity and the sac transfixed at the deep ring. Polypropylene mesh was placed in the inguinal canal and hernioplasty done. The patient was discharged on the 2nd postoperative day in a stable condition and followed up in the OPD. Scrotal support was advised and the sutures removed on the 10th postoperative day. Further followup period was uneventful.



*Corresponding author: **Dr. Ravinder Kumar**

Government Medical College, Kathua , Jammu & Kashmir

Figure showing normal appendix in the indirect inguinal hernia sac.

Discussion:

The pathogenesis of Amyand’s hernia associated acute appendicitis remains controversial. Previous studies indicated that muscle contractions or sudden increases in intra-abdominal pressure might compress the appendix causing decreased blood supply resulting in inflammation^{4,5}. Moreover, an extraluminal obstruction of the appendix usually causes appendicitis due to pressure in the hernia neck rather than intraluminal obstruction^{3,4}.

A definitive preoperative diagnosis of Amyand’s hernia is rare since the diagnosis is usually made during the surgery. Physical examination, laboratory examination and imaging are not helpful in the pre-operative diagnosis of Amyand’s hernia. Imaging modality like CT scan can facilitate the diagnosis of Amyand’s hernia. However, CT is usually not the first choice for an uncomplicated inguinal hernia in a patient admitted in the emergency department⁶. Therefore, the diagnosis of Amyand’s hernia will be missed at that time. Sonography has been reported as a valuable examination in the preoperative screening of Amyand’s hernia since it is cheap and convenient for patients with pain^{7,8}. However, a preoperative diagnosis of Amyand’s hernia based on ultrasound alone depends on the proficiency of the operator, and for that reason, remains a relatively unreliable imaging modality to accurately diagnose Amyand’s hernia⁹. Therefore, laparoscopic surgery can function as a diagnostic and therapeutic approach. Recently, a systematic review indicated that CT was the definitive diagnostic modality in patients with preoperative diagnosis¹⁰. Therefore, the diagnosis of Amyand’s hernia can be best made by laparoscopy or laparotomy.

Losanoff and Basson created a classification system for Amyand’s hernia based on different conditions they identified (Table 1)

Table 1 Four types of Amyand’s Hernia

Classification	Description	Surgical management
Type 1	Normal appendix within an inguinal hernia	Hernia reduction, mesh repair, appendectomy in young patients
Type 2	Acute appendicitis within an inguinal hernia, no abdominal sepsis	Appendectomy through hernia, primary endogenous repair of hernia, no mesh
Type 3	Acute appendicitis within an inguinal hernia, abdominal wall, or peritoneal sepsis	Laparotomy, appendectomy, primary repair of hernia, no mesh
Type 4	Acute appendicitis within an inguinal hernia, related or unrelated abdominal pathology	Manage as types 1 to 3 hernia, investigate or treat second pathology as appropriate

The current generally accepted treatment algorithm for Amyand’s hernia is essentially contingent on the condition of the appendix within the hernia sac. A normal looking appendix in the hernia sac does not always require appendectomy. Appendectomy adds the risk of infection to an otherwise clean procedure. In the cases where an inflamed, suppurative or perforated appendicitis are encountered, no prosthetic material should be used because of the increased risk of surgical site infection. Whether to remove or leave behind a normal appendix is a clinical dilemma because no evidence-based information exists. The decision should be based on common sense, taking into account the patient’s age, life expectancy, life-long risk of developing acute appendicitis, and the size and overall anatomy of the appendix. According to the Losanoff and Basson classification, our patient had a type 1 hernia where the appendix was normal appearing and was treated by reduction of the herniated contents and herniotomy followed by mesh hernioplasty. Appendectomy was not done as the appendix was short in size and did not show any signs of inflammation. The follow-up period remained uneventful.

CONCLUSION

Amyand’s hernia is a rare presentation of inguinal hernias and its preoperative diagnosis remains a challenge. CT and ultrasonography are helpful but the definitive diagnosis is made by laparoscopy. Treatment options should be tailored based on the patient’s condition and the type of Amyand’s hernia. Attention should be paid to the use of antibiotics and drainage in the operative area.

References

1. Amyand C. Of an inguinal rupture, with a pin in the appendix coeci, incrusted with stone; and some observations on wounds in the guts. *Phil Trans R Soc Lond.* 1735;39: 329-42.
2. Adamantios Michalinos, Demetrios Moris, Spyridon Vernadakis, Amyand’s hernia: a review, *Am. J. Surg.* 207 (2013), <http://dx.doi.org/10.1016/j.amjsurg.2013.07.043>.
3. Barut I, Tarhan ÖR. A rare variation of amyand’s Hernia: gangreneous appendicitis in an incarcerated inguinal hernia sac. *Eur J Gen Med.* 2008;5(2):112–4.
4. Solecki R, Matyja A, Milanowski W. Amyand’s hernia: a report of two cases. *Hernia.* 2003;7(1):50–1.
5. Abu-Dalu J, Urca I. Incarcerated inguinal hernia with a perforated appendix and periappendicular abscess: report of a case. *Dis Colon Rectum.* 1972;15(6):464–5.
6. Hamedghodusi J, Shahram P, Nejad SZ, Shima E, Masumehghodusi J. Left-sided Amyand hernia. *Ann Saudi Med.* 2009;29(4):321–2.
7. Coulier B, Pacary J, Broze B. Sonographic diagnosis of appendicitis within a right inguinal hernia (Amyand’s hernia). *J Clin Ultrasound Jcu.* 2010;34(9):454–7.
8. Bachir E, Elie C, Jean-Louis A. Transabdominal laparoscopic repair of Amyand’s hernia: a case report. *Case Rep Surg.* 2011;2011:1–2.
9. Singal R, Mittal A, Gupta A, Gupta S, Sahu P, Sekhon MS. An incarcerated appendix: report of

three cases and a review of the literature. *Hernia*. 2012;16(1):91-7.

10. Papaconstantinou D, Garoufalia Z, Kykalos S, Nastos C, Tsapralis D, Ioannidis O, et al. Implications of the

presence of the vermiform appendix inside an inguinal hernia (Amyand's hernia): a systematic review of the literature. *Hernia*. 2020;24(5):951-9.

How to cite this article:

Ravinder Kumar., Junaid Nabi Wani., Deepti Chanjotra and Syed Ajaz. (2024). Amyand's hernia: A case report and review of literature. *International Journal of Current Advanced Research*.13 (06), pp.3148-3150.
