International Journal of Current Advanced Research
ISSN: O: 2319-6475, ISSN: P: 2319-6505, Impact Factor: SJIF: 5.995
Available Online at www.journalijcar.org
Volume 7; Issue 1(C); January 2018; Page No. 8927-8930
DOI: http://dx.doi.org/10.24327/ijcar.2018.8930.1457

Research Article

OCCIPITALIZATION OF THE ATLAS VERTEBRA: IT'S EMBRYOLOGICAL AND CLINICAL SIGNIFCANCE

Bhaskar B.Reddy*., Meghana Mishra., P.G.Khanwalkar., Arjun S.Parmar and Harsh Chawre

Department of Anatomy, Shyam Shah Medical College, Rewa (Madhya Pradesh) PIN: 486001

ARTICLE INFO

Article History:
Received 15th October, 2017
Received in revised form 25th November, 2017
Accepted 28th December, 2017
Published online 28th January, 2018

Key words:
Atlas, Foramen magnum, Occipitalization

ABSTRACT

Background: The *atlas* is the first cervical *vertebra*, commonly called C1. Occipitalization of the atlas, occipitocervical synostosis, or atlanto-occipital fusion is one of the most common skeletal abnormalities of the upper cervical spine. Its incidence ranges from 0.08%-3% in general population. Occipitalization of the atlas result in narrowing of foramen magnum which may compress the brain stem, vertebral artery and cranial nerves. Knowledge of occipitocervical synostosis is important for the surgeons during the surgeries in the craniovertebral region.

Methods: In the present study a sample of 84 adult human skulls were examined in the department of Anatomy, Shyam Shah Medical College, Rewa (MP), for evidence of atlanto-occipital fusion. For the study non pathological adult skulls of unknown sex were included.

Results: Total two specimens exhibited occipitalization of atlas. One specimen exhibited atlanto-occipital fusion, in which the total fusion of the atlas vertebra with the skull was seen. It also exhibited large anterior tubercle and hypoglossal canal was present only on right side. In another specimen, anterior arch of the atlas along with the anterior tubercle was completely fused with the anterior rim of foramen magnum of the occipital bone except for a slit-like opening above the left anterior arch of atlas near the anterior tubercle. It also exhibited hypoglossal canal on both sides with normal size and shape.

Conclusions: The partial or complete assimilation of the atlas may have resulted due to disruption in the separation of the caudal part of the first sclerotome from the cranial part of the first sclerotome. The knowledge about pre existing malformations and their clinical and radiological appearance is important during diagnostic imaging studies. This condition may also be of importance to physiotherapist dealing with the neck pain.

INTRODUCTION

First cervical vertebra is also known as Atlas, because it supports the globe of the head. The atlas is a ring shaped bone without a body. It has an anterior arch, a posterior arch and two lateral masses. Occipitalization is a congenital synostosis of the atlas to the occiput, which is a result of failure of segmentation and separation of the most caudal occipital sclerotome and the first cervical sclerotome during the first few weeks of fetal life[1].

Occipitalization of the atlas or atlanto- occipital fusion is one of the most common osseous anomalies of the craniovertebral junction[2]. Occipitalization of the atlas is an important congenital malformation because of its close relationship to the spino-medullary region and it can produce a wide range of neurological signs and symptoms such as torticollis, restricted neck movements and/or abnormal short neck[3]. The clinical findings may be the headache, neck pain, numbness and pain in the limbs, weakness, abnormal head posture. Occipitalization also results in weakness and ataxia of the lower extremities while numbness and pain in the upper extremities. Apart from this, vertebral artery compression or even its total occlusion in the bony canal leading to dizziness, seizures, mental deterioration and syncope has also been reported[4]. This anatomical variation may remain unnoticed until the patient undergoes clinical or radiological investigation for the treatment of symptoms or may be encountered as surgical, autopsy findings or during morphological studies of skull.

The aim of the present study is to demonstrate the prevalence of atlanto-occipital fusion and to describe, in detail, the gross skeletal changes that occur in such an anomaly. The knowledge of this uncommon anatomical variation in the cranio-vertebral junction is imperative for clinicians.

Corresponding author:* **Bhaskar B.Reddy
Department of Anatomy, Shyam Shah Medical College, Rewa (Madhya Pradesh) PIN: 486001

METHODS

In the present study a sample of 84 adult human skulls were examined in the department of Anatomy, Shyam Shah Medical College, Rewa (MP), for evidence of atlanto-occipital fusion. For the study non pathological adult skulls of unknown sex were included. The base of skulls was observed for the presence of atlanto-occipital fusion. The skulls which showed atlanto-occipital fusion were studied in detail and their photographs were taken. In the skulls which showed the fusion, the antero-posterior diameter, transverse diameter of foramen magnum and inferior articular facets of atlas were measured using Vernier calipers.

RESULTS

Out of the 84 adult human dry skulls studied, 2 (2.38%) skulls showed occipitalization of atlas.

Specimen 1 (Fig.1)

- The anterior arch of the atlas along with the anterior tubercle was completely fused with the anterior rim of foramen magnum of the occipital bone.
- Size of the anterior tubercle was larger than the normal.
- The posterior arch was partially broken and fused with the posterior rim of foramen magnum on right side.
- The superior articular facets of the atlas vertebra was completely fused with the occipital condyles on the right and left sides.
- The specimen showed no fusion of the transverse processes with the occipital bone on both the sides.
- The foramen transversaria were seen to be normal in appearance on both the sides
- The inferior articular facets of atlas vertebra were rounded in outline on the right side and oval on the left side and directed downward on both the sides.
- The antero-posterior diameter of the foramen magnum was 33 mm and the transverse diameter was 25 mm.
- Hypoglossal canal was observed on the right side and not on the left side.

IAF: Inferior articular process
FT: Foramen Transversarium
RTP: Right transverse process
LTP: Left transverse process
AA: Anterior arch
AT: Anterior tubercle
PA: Posterior arch
RHC: Right hypoglossal canal
FM: Foramen magnum

Fig 1 Occipitalization of Atlas vertebra- Antero inferior view

Specimen 2 (Fig.2)

- The anterior arch of the atlas along with the anterior tubercle was completely fused with the anterior rim of foramen magnum of the occipital bone except for a slit-like opening above the left anterior arch of atlas near the anterior tubercle.
- Size of the anterior tubercle appears to be normal.
- The upper margin of the posterior arch was completely fused with the posterior rim of foramen magnum.
- The superior articular facets of the atlas vertebra was completely fused with the occipital condyles on the right and left sides.
- The specimen showed very short transverse processes on both the sides.
- The inferior articular facets of atlas vertebra were rounded in outline on the right side and oval on the left side and directed downward on both the sides
- The antero-posterior diameter of the foramen magnum was 31 mm and seems to be reduced due to encroachment of the posterior arch. The transverse diameter was 25 mm.
- Hypoglossal canal was observed on both sides with normal size and shape.

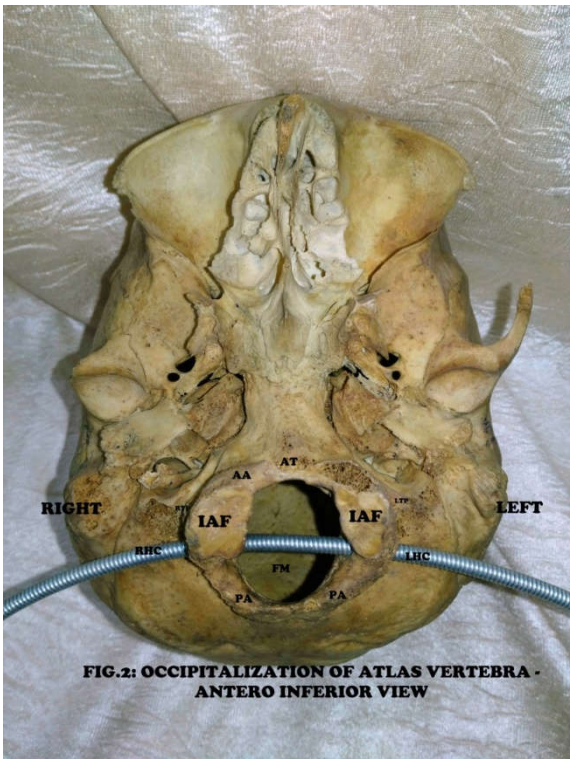

Fig 2 Occipitalization of Atlas vertebra- Antero inferior view

Table 1 Morphometric measurements of the skulls with atlanto-occipital fusion

S. no.	Measurements	Skull-1	Skull-2
1.	Anteroposterior diameter of foramen magnum	33 mm	31 mm
2.	Transverse diameter of foramen magnum	25 mm	25 mm
3.	Anteroposterior diameter of right condylar facet	16 mm	17 mm
4.	Transverse diameter of right condylar facet	19 mm	13 mm
5.	Anteroposterior diameter of left condylar facet	20 mm	11 mm
6.	Transverse diameter of left condylar facet	13 mm	17 mm

Table 2 Incidence of Atlanto–occipital fusion

authors Name	incidence = No. of cases/ total no. of skulls studied	Percentage (%)
Hussain Saheb *et al*., [16]	1/125	0.80
Sharma *et al*., [4]	2/70	2.85
Seema *et al*., [17]	2/100	2
Kassim *et al*., [18]	2/55	3.63
Surekha *et al*., [6]	1/150	0.67
Mudaliar *et al*.,[19]	2/200	1
Present study	2/84	2.38

DISCUSSION

Atlanto-occipital fusion was first described by Rokitansky in 1884 and demonstrated roentgenographically by Schuller in 1911[5,6].

The development of atlas is essential for understanding congenital anomalies. The body of atlas vertebra derives from the primitive fourth occipital and first cervical sclerotomes. Three or more ossification centers form the atlas. Usually one midline center builds the anterior arch in the seventh week of gestation. At the same time, two ossification centers form the lateral masses[7].

The caudal half of the first cervical sclerotome combines with the rostral half of the second cervical sclerotome to form the first cervical vertebra. Unification between the ossified atlas parts occurs at five to nine years of age [8,9]. The ossification usually proceeds perichondrally.

Patients with occipitalization of atlas do not develop the symptoms until the second decade of life. Clinical manifestations associated with atlanto occipital fusion are mainly attributed to the gradual increase in ligamentous laxity of the transverse ligament in relation to the odontoid process. The flexion and extension movements of neck lead to the compression of spinal cord. The chances of regeneration of the central nervous system decreases with increasing age and repeated injuries to the nerves from the odontoid may result in the neurological symptoms. Atlanto-occipital fusion is associated with narrowing of foramen magnum, compression of spinal cord or brain stem[10].

Compression of spinal cord or the brain stem can produce signs and symptoms like simple headache to a full blown neurological syndrome. The neurological complications could be the result of compression of spinal cord, nerves and vessels. The symptoms of neurological syndrome can be occipital headache, neck pain, numbness and pain in the limbs, weakness and abnormal head posture[4,11,13].

Spinal cord compression always occurs when the sagittal spinal canal diameter behind the odontoid process is less than or equal to 14 mm. Spinal cord compression is possible when the sagittal canal diameter is between 15 mm-17 mm and almost never occurs at a distance of 18 mm or more[12].

Serious clinical manifestation such as myopathy, limitations of neck movements, muscular weakness and atrophy and sensory loss also reported. It has been reported that patients with atlanto-occipital fusion can have tonic or clonic convulsions[13,14].

CONCLUSIONS

The knowledge about pre existing malformations and their clinical and radiological appearance is important during diagnostic imaging studies. Fusion associated with the reduction in dimensions of foramen magnum is definitely significant for diagnostic and therapeutic purposes to clinicians. The knowledge of assimilation may be of importance to orthopedic surgeons dealing with the pathologies of upper cervical spine as it may cause anesthetic problems like failure of cisternal puncture. This condition may also be of importance to physiotherapist dealing with the neck pain.[15]

Acknowledgements

The author would like to express his gratitude to Dr. P.C.Dwivedi, Dean, Shyam Shah Medical College, Rewa (M.P.) for giving permission to study human skeletal remains.

Declarations

Funding: None
Conflict of interest: None
Ethical approval: Study involved only dry human skeletal material, so ethical approval is not required

References

1. Guebert GM, Yochum TR, Rowe LJ. Congenital anomalies and normal skeleton variants. In: Essentials of Skeletal Radiology. Yochum TR, Rowe LJ, eds. Baltimore, Williams & Wilkins. 1987; 197-306.
2. Bopp A, Frauendorf E. Paracondylar process versus paramastoid process - a contribution to its nomenclature and topographic anatomy. *Homo*. 1996; 47: 163-176.
3. Khamanarong k *et al*, Occipitalization of the atlas: Its incidence and clinical implications. *Acta Medica Academica* 2013;42(1):41-45.
4. M Sharma, B Singh, A Abhaya, H Kumar. Occipitalization of atlas with other associated anomalies of skull. *Eur J Anat.* 2008;12 (3):159-67.
5. Sangeeta RJ, Ila SM, Jitendra RK. An unusual case of unilateral atlanto-occipital assimilation with skull asymmetry. *National journal of medical research.* 2012; 2(2): 238-40.
6. Jadhav SD, Ambali MP, Patil RJ, Doshi MA, Roy PP. Assimillation of atlas inIndian dry skulls. *JKIMSU.* 2012; 1:102-6.
7. C. E. Brown, "Complete absence of the posterior arch of the atlas," The Anatomical Record, vol. 81, pp. 499-503, 1941.
8. G. Fiorani-Gallotta and G. Luzzatti, "Complete absence of the posterior arch of the atlas," *Archivio di Ortopedia*, vol. 68, no. 5, pp. 753-778, 1955.
9. Sadler TW. Langman's Essential Medical Embryology.10th Ed., Baltimore, Lippincott William and Wilkins.2007: 125-141.
10. Gholve PA, Hosalkar HS, Ricchetti ET, Pollock AN, Dormans JP, Drummond DS. Occipitalization of the atlas in children, Morphologic classifcation, associations, and clinical relevance. *J Bone Joint Surgery Am.* 2007;89:571-78.
11. Luevitoonvechkij S, Sirirungruangsarn Y, Khunsree S, Thiranont N. A modified pin and wiring technique for occipitocervical fusion in a child with Occipitalization of the atlas: a case report. *Chiang Mai Med J.* 2010; 48(1):35-39.
12. Alvin D. Greenberg; atlanto-axial dislocations, *brain*, volume 91, issue 4, 1 december 1968, pages 655-684, https://doi.org/10.1093/brain/91.4.655
13. Jayanti V, Kulkarni R, Kulkarni R N. Atlanto-Occipital Fusion - Report of Two Cases. *J Anat. Soc. India.* 2003; 52 (1): 71-73.
14. Campos D, Silva TH, Ellwanger JH, Goerck ML, Kipper JF, Piazza JL *et al*. Atlanto-occipital fusion and its neurological complications: a case report. *J. Morphol. Sci.* 2012; 29(2):111-13.

15. Nayak S, Vollala VR, Raghunathan D. Total fusion of atlas with occipital bone: a case report. *Neuroanatomy*. 2005; (2):39-40.
16. Saheb HS, Mavishetter GF, Thomas ST, Prasanna LC, Muralidhar P. Occipitalization of Atlas: A case report. *J. Biomedsci and Res.* 2010; 2:73-75.
17. Seema, Mahajan A. Synostosis of atlas with occipital bone-occurrence and clinical application. *IJABPT.* 2011; 2(4):363-65.
18. Kassim NM, Latiff AA, Das S, Ghafar NA, Suhaimi FH, Othman F, *et al*. Atlantooccipital fusion: an osteological study with clinical implications. *Bratisl Lek Listy.* 2010; 111(10):562-65.
19. Mudaliar R.P, Shailaja shetty, Komala Nanjundaiah, Prathap Kumar, Jyothi KC. An Osteological Study of Occipitocervical Synostosis: Its Embryological and Clinical Signifcance. *Journal of Clinical and Diagnostic Research.* 2013 Sept, Vol-7(9): 1835-1837.

How to cite this article:

Bhaskar B.Reddy *et al* (2018) 'Occipitalization of the Atlas Vertebra: It's Embryological and Clinical Signifcance', *International Journal of Current Advanced Research,* 07(1), pp. 8927-8930.
DOI: http://dx.doi.org/10.24327/ijcar.2018.8930.1457

****