

## **UNUSUAL PRESENTATION OF POLY-CYSTIC OVARIES REQUIRING SURGICAL MANAGEMENT- A CASE REPORT**

**Anoosha K Ravi and Krishna Agarwal\***

Department of Obstetrics and Gynecology, Maulana Azad Medical College and associated LokNayak Hospital, New Delhi, India

### **ARTICLE INFO**

**Article History:**

Received 18<sup>th</sup> October, 2017

Received in revised form 21<sup>st</sup>

November, 2017

Accepted 05<sup>th</sup> December, 2017

Published online 28<sup>th</sup> January, 2018

**Key words:**

Polycystic ovaries, Polycystic ovarian syndrome

### **ABSTRACT**

Polycystic ovarian syndrome (PCOS) is characterised by menstrual irregularities, hyperandrogenic features and polycystic ovaries (PCO). Though it is a commonly diagnosed condition on OPD basis, sometimes the presentation can create a diagnostic challenge. We are reporting one such case of a young girl who came to us with unusual presentation. She had a huge abdomino-pelvic mass mimicking malignant ovarian mass on laparotomy and frozen section, leading to removal of the mass, which on histopathology was reported to be polycystic ovary. In adolescent girls presenting with large ovarian mass, diagnosis of PCOD should be kept in mind before its surgical removal.

*Copyright©2018 Anoosha K Ravi and Krishna Agarwal. This is an open access article distributed under the Creative Commons Attribution License, which permits unrestricted use, distribution, and reproduction in any medium, provided the original work is properly cited.*

### **INTRODUCTION**

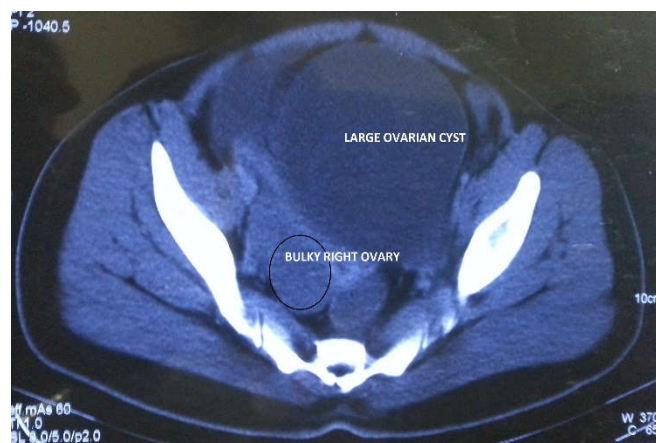
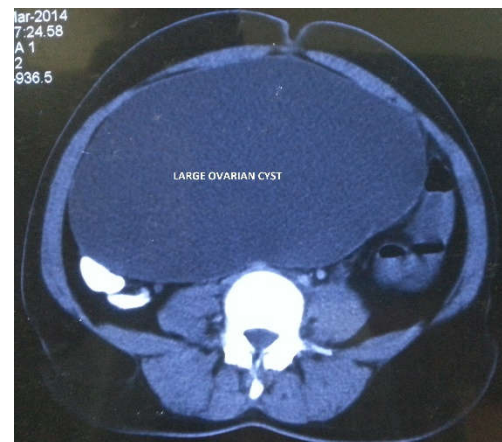
Polycystic ovary is a benign condition but has a varied spectrum of presentation which can delay the diagnosis. The diagnosis is unequivocal if there are features of hyperandrogenism, ovarian cysts with menstrual irregularities in an obese woman. But more often than not, it is uncommon to find all the features in every PCOD case. With the following case, we would like to bring the medical practitioners' attention to the much severe ways a PCOD case can present with and cloud the diagnosis needing an exploratory laparotomy and inadvertent removal of ovary.

#### **Case description**

A 18 year old, moderately built, unmarried girl presented with history of infrequent menstrual cycles since menarche and weight gain since 2 years. On examination, a huge abdominopelvic mass of 30-32 week size (25×20cm) was found. It was non-tender with restricted mobility. Patient was admitted and worked up with a suspicion for malignancy. Tumor markers were within normal limits. CA125-14.5U/ml, βHcg-<0.1mIU/ml, AFP-1ng/ml, CEA-<0.2ng/ml, Inhibin A-1.3pg/ml and Inhibin B-52pg/ml. Contrast enhanced computed tomography of abdomen and pelvis showed well defined homogenous cystic lesion in right iliac fossa of size 22×12×19 cm with bulky right ovary of 55×26mm with no evidence of calcification or soft tissue component.

**\*Corresponding author: Krishna Agarwal**

Department of Obstetrics and Gynecology, Maulana Azad Medical College and associated LokNayak Hospital, New Delhi, India



**Figure 1** computed tomography image of the abdomino-pelvic mass

Exploratory laparotomy revealed a huge solid cystic right sided ovarian mass with 25×20cm cystic component and 6×8cm solid component with papillary excrescences. We proceeded with right sided ovariectomy and salpingectomy, pelvic lymphadenectomy, peritoneal biopsy and omental biopsy.

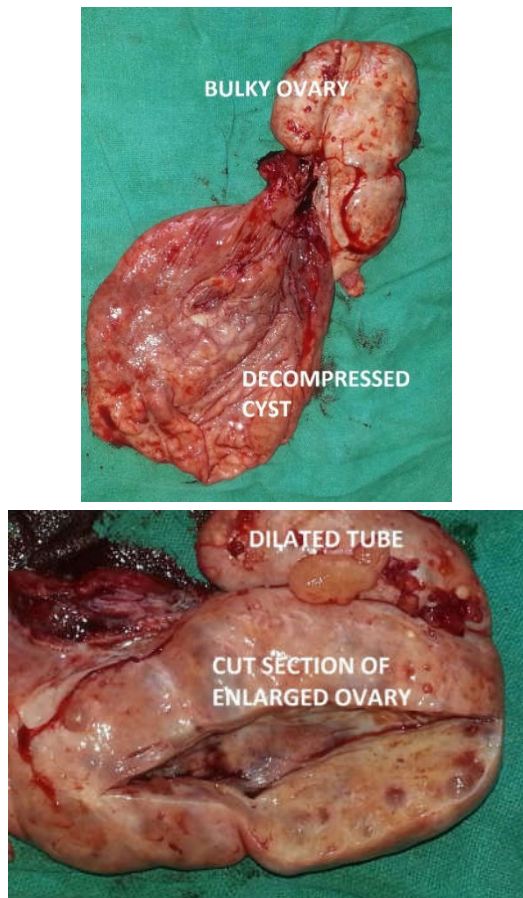


Figure 2 Gross features of the ovarian mass

Frozen section was reported as sex cord stromal tumor with negative lymph nodes. However, final histopathology report was giant polycystic ovary with hydrosalpinx. Patient was discharged on oral combined contraceptive pills. On subsequent follow up she was healthy and had regular menstrual cycles.

## DISCUSSION

The two major criteria to diagnose PCOS or Stein- Leventhal syndrome are an ovulation and hyperandrogenism. Other frequently encountered manifestations like insulin resistance, hirsutism, obesity, psychiatry disorders and ultrasonographic evidence of PCOS qualify only as minor criteria. On ultrasound, polycystic ovaries (PCO) are characterised by 26 or more follicles measuring 2-9mm with >10cm ovarian volume<sup>1</sup>. Polycystic ovarian syndrome is prevalent in 5-10% of the reproductive age women<sup>2</sup>. PCOS features may be difficult to distinguish from symptoms of puberty; thus posing a diagnostic difficulty in adolescents.

In the above described case, huge abdominopelvic mass with irregular menstrual cycles, was mimicking a malignant picture. Only the final histopathology report gave a conclusive diagnosis. Large cystadenoma with PCOS is a rare presentation. In the literature, a similar PCOS case of a 17year old was found with increasing size of ovarian cyst<sup>3</sup>. She had a large cyst of about 30cm when she underwent salpingoophorectomy. Thus when large masses in adolescents are encountered, tumor should be considered if there are solid cystic components or positive tumor markers or in ones that do not resolve or reduce in serial monitoring. Surgical removal of masses is warranted but oophorectomy needs careful consideration.

This atypical presentation clearly stress upon the need for high degree of suspicion for PCOD in young girls with huge ovarian masses with irregular cycles. Large ovarian cysts in PCOD may need emergency laparotomy in cases of ovarian torsion or haemorrhage<sup>4</sup>. Keeping in mind the future fertility aspect of these young girls, PCOD cases should be managed more in lines of conservative manner. A careful work up for malignant looking polycystic ovaries prevent inadvertent ovarian sacrifice.

## References

1. Lujan ME, Jarett BY, Brooks ED, Reines JK, Peppin AK, Muhn N, Haider E, Pierson Ra, Chizen DR. Updated ultrasound criteria for polycystic ovary syndrome: reliable threshold for elevated follicle population and ovarian volume. *Hum Reprod.* 2013;28(5):1361-8.
2. Allahbadia GN, Merchant R. Polycystic ovary syndrome in the Indian subcontinent. *SeminReprod Med.* 2008;26(1):22-34.
3. Nishit Patel, Greg Dupuis, Robert Wild. Giant ovarian cyst in an adolescent with PCOS. *Consultant.* 2014;54(1):41-3.
4. Sheroo Zamindar. Unusual presentation of acute ovarian torsion in PCOD. *Researchgate.* July 2012. <http://dx.doi.org/10.1016/j.apme.2012.06.003>.

### How to cite this article:

Anoosha K Ravi and Krishna Agarwal (2018) 'Unusual Presentation of Poly-Cystic Ovaries Requiring Surgical Management- A Case Report', *International Journal of Current Advanced Research*, 07(1), pp. 9084-9085.  
DOI: <http://dx.doi.org/10.24327/ijcar.2018.9085.1487>

\*\*\*\*\*