



KNOWLEDGE, ATTITUDE AND PRACTICE OF VESTIBULOPLASTY IN CD PATIENT AMONG THE DENTAL PRACTITIONERS

Oviya V.J*., Dhanraj and Anandhi

Saveetha Dental College and Hospitals, Chennai - 600077

ARTICLE INFO

Article History:

Received 9th April, 2017

Received in revised form 15th May, 2017

Accepted 25th June, 2017

Published online 28th July, 2017

Key words:

Knowledge, awareness, practice, vestibuloplasty, complete denture

ABSTRACT

Background : Vestibuloplasty is a surgical procedure whereby the oral vestibule is deepened by changing the soft tissue attachments. It is used to increase the denture foundation area and improve the quality of the soft tissues available for support in case of primarily involving tissue shrinkage.

Aim & Objective: To study the knowledge, attitude and practice of vestibuloplasty in CD patient among dental practitioners

Materials and methods: A prepared questionnaire was distributed to 100 dental practitioners regarding their knowledge about the vestibuloplasty and the results were studied.

Results and conclusion: The knowledge, awareness and practice among dental practitioners regarding vestibuloplasty is very poor. Majority of practitioners have a poor knowledge about the vestibuloplasty and its effectiveness. Hence efforts must be taken to create awareness and training should be given to increase its practice.

Copyright©2017 Oviya V.J., Dhanraj and Anandhi. This is an open access article distributed under the Creative Commons Attribution License, which permits unrestricted use, distribution, and reproduction in any medium, provided the original work is properly cited.

INTRODUCTION

Pre-prosthetic surgery is that part of oral and maxillofacial surgery which restores oral function and facial form. This is concerned with surgical modification of the alveolar process and its surrounding structures to enable the fabrication of a well-fitting, comfortable, and esthetic dental prosthesis. The ultimate goal of pre-prosthetic surgery is to prepare a mouth to receive a dental prosthesis by redesigning and smoothening bony edges. Wearing dentures for prolonged period manifests adverse changes in the denture-bearing areas due to change in the size of the jaw bones resulting in ill-fitting and painful dentures. Pre-prosthetic surgery is an integral part of oral and maxillofacial surgery and prosthodontics. It comprises both basic procedures and sophisticated techniques of reconstructions and rehabilitation of oral and maxillofacial region. One of such procedures is vestibuloplasty which can be done by enlarging the denture bearing areas and improve the quality of the soft tissues available for support in case of primarily involving tissue shrinkage[1]. It is the surgical procedure to restore alveolar ridge height by lowering muscles attaching to the buccal, labial and lingual aspect of the jaws.

The purpose of this study is to study the knowledge, attitude and practices of vestibuloplasty among the dental practitioners.

*Corresponding author: Oviya V.J

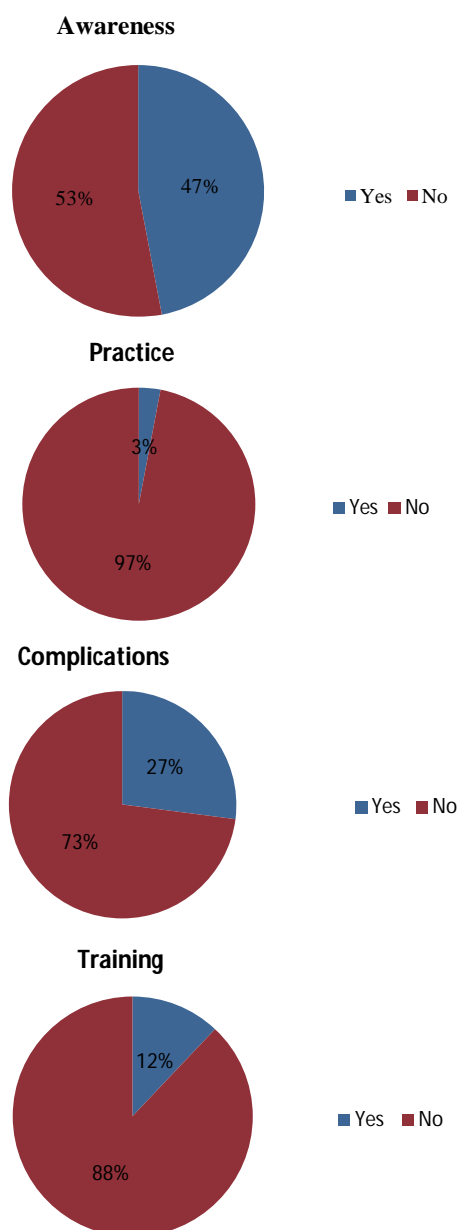
Saveetha Dental College and Hospitals, Chennai - 600077

MATERIALS AND METHODS

This questionnaire based study was conducted among dental practitioners of Saveetha dental college. A questionnaire was prepared and was given to about 100 dental practitioners. It consists of questions which studied the attitude and knowledge of dentists. Questions were on factors affecting the procedure, complications and various types of vestibuloplasty. The responses were recorded and analysed.

RESULTS

In this study, a total of 100 dental practitioners were participated. Out of 100, 68% of the participants were females and 32% were males. Among them, only 47% of the practitioners were aware of this vestibuloplasty while 12 were trained in this procedure. But only 3% of the practitioners are practicing this procedure. Out of 100, 28% of the practitioners know about this preprosthetic procedure and 25 know about the factors which can affect this procedure. 34% of the practitioners were aware of the types of vestibuloplasty but only 24% of the participants were aware about the procedures in each type. About 27% were aware of the complications related to this procedure.



DISCUSSION

A total of 100 dental practitioners were participated in this study. Among them, only 47% of the participants were aware of this vestibuloplasty. Out of 47 participants, 12 were trained in this procedure, but only 3% of the students were practicing this procedure. Out of 100, 28% of the practitioners know about this preprosthetic procedure and 25 know about the factors which can affect this procedure such as age, amount and consistency of mucous membrane, presence of bony projections and ridges etc. Vestibuloplasty repositions mucosa, muscle insertions, and increases denture flange area in turn stability of prosthesis[4]. Bhavna Jha Kukreja *et.al* reported that vestibuloplasty with periosteal fenestration operation, provide retention and stability of mandibular prosthesis[5]. About 30% of the students are aware that it is done by either increasing the height and width of the bone and gum or by lowering the floor and roof of the mouth. 34% of the practitioners were aware of the types of vestibuloplasty such as Mucosal advancement vestibuloplasty, secondary epithelization vestibuloplasty and grafting vestibuloplasty and only 24% of the practitioners were aware of the procedures in

each type. Basavaraj C. Sikkerimath *et. al* did a study to clinically assess the vestibular sulcus depth in vestibuloplasty using Clark's technique with and without amnion as graft material. He concluded that amnion graft is viable and reliable option that promote early healing and maintains postoperative vestibular depth[3]. Gerry M. Raghoobar *et.al* did a study to detect whether autologous cultured sheets of mucosa can serve as a dressing for wounds caused by vestibuloplasty. He concluded that cultured mucosa can serve as a proper dressing for mucosal defects after vestibuloplasty[6]. Farrell CD *et.al* presented a technique of one-stage autogenous bone grafting and submucous vestibuloplasty for reconstruction of the atrophic maxillary alveolar ridge and concluded it as the valuable technique for use in the atrophic maxilla[7]. About 27% were aware of the complications related to this procedure. Scott C. Shafer *et.al* described a technique that allows simultaneous posterior mandibular ridge augmentation and anterior sulcus deepening and proved that it improves the denture bearing area of the mandible more than vestibuloplasty alone[8]. E.M. Boerrigter *et.al* compared the denture satisfaction and chewing ability of edentulous patients treated with dental implant-retained overdentures with or without previous preprosthetic surgery. He concluded that overdentures retained by dental implants or complete dentures made after a vestibuloplasty and deepening of the floor of the mouth provide a more satisfactory solution for denture-related problems than complete dentures alone[9]. Jagannadham Vijay Kumar *et.al* reported that Kazanjian technique provides adequate attached gingiva for successful prosthesis. Extension of vestibular depth enables fabrication of better denture flange with improved oral hygiene without hospitalisation and additional surgery for grafts[10].

CONCLUSION

From this study, it is clear that knowledge of vestibuloplasty among dental practitioners is very low. Hence efforts must be taken to create awareness and training should be given to increase its practice.

References

1. Devaki VN, Balu K, Ramesh SB, Arvind RJ, Venkatesan Pre-prosthetic surgery: Mandible. *J Pharm Bioallied Sci.* 2012; 4:S414-6.
2. Vestibuloplasty/ certified fixed orthodontic courses, Indian dental academy,
3. Comparison of vestibular sulcus depth in vestibuloplasty using standard clark's technique with and without amnion as graft material. Basavaraj C. Sikkerimath, Satyajit Dandagi, and Deeptha Jayapalan, *Annals of maxillofacial surgery*, 2(1): 30-35, Jan-June 2012.
4. Kazanjian VH, Surgery as an aid to more efficient service with prosthetic dentures *J Am Dent Assoc* 1935 22(4):566-81.
5. Periosteal fenestration vestibuloplasty procedure for sulcus deepening in a hemimandibulectomy patient following implang therapy. Bhavna Jha Kukreja, Udayan Gupta, Vidya Dodwad *et.al*, *journal of Indian society of periodontology*, volume:18, issue: 4, 508-511, 2014
6. Use of cultured mucosal grafts to cover defects caused by vestibuloplasty, Gerry M. Raghoobar, Anna M. Tomson, Arjan Vissink. *Journal of oral and*

- maxillofacial surgery*, Vol.53 (8): 872-878, August 1995.
7. One-stage interpositional bone grafting and vestibuloplasty of the atrophic maxilla, Farrell CD, Kent JN, Guerra LR, *Journal of oral surgery*, 34(10):901-906, 1976.
 8. Hydroxyapatite augmentation of the mandible with simultaneous mucosal graft vestibuloplasty, Scott C. Shafer, Anthony G. Parnell, *Journal of oral and maxillofacial surgery*, Vol.43(11):749-750, Nov 1984.
 9. Patient satisfaction and chewing ability with implant-retained mandibular overdentures: A comparison with new complete dentures with or without preprosthetic surgery. E. M. Boerrigter, Stegenga. B, Raghoobar. G. M. *et.al*, *J Oral Maxillofac Surg*. 1995 Oct; 53(10):1167-73.
 10. Jagannadham Vijay Kumar, Pandi Srinivas Chakravarthi, *et.al*,. Anterior Ridge Extension Using Modified Kazanjian Technique In Mandible- A Clinical Study. *Journal of Clinical and Diagnostic Research [serial online]* 2016 Feb [cited: 2017 May 31] 02 ZC21 - ZC24.

How to cite this article:

Oviya V.J., Dhanraj and Anandhi (2017) 'Knowledge, Attitude and Practice of Vestibuloplasty in Cd Patient Among the Dental Practitioners ', *International Journal of Current Advanced Research*, 06(07), pp. 4951-4953.
DOI: <http://dx.doi.org/10.24327/ijcar.2017.4953.0620>
